

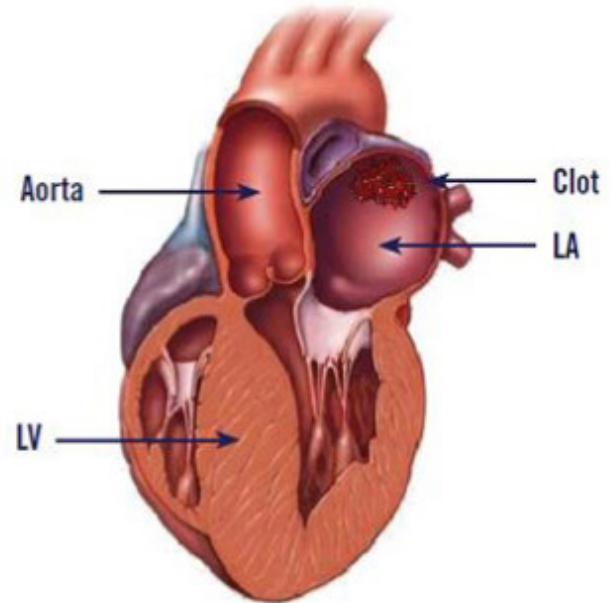
Feline Arterial Thromboembolism (FATE, Saddle Thrombus)

Frequently, left atrial enlargement is a secondary change in cats with cardiomyopathy (heart muscle disease).

Clot development in the enlarged left atrium is a common complication. Clots within the left atrium can remain attached to the surface of the atrium, or they can enter circulation and block the arteries they enter.

Most commonly the clot exits the heart, travels down the aorta, and lodges in the saddle of the iliac arteries thus interrupting the flow of blood to the rear legs. This is seen clinically as a sudden onset of weakness and inability to use the rear legs, pain, vocalization, and often respiratory difficulties.

Therapy is designed to relieve pain while collateral circulation develops, combat fluid build-up from congestive heart failure, and to decrease future clot development.



In most patients, gradual signs of recovery are evident within 72 hours. Unfortunately prognosis with this condition is often poor. 30-45% of cats do not survive their initial hospitalization. Many cats develop congestive heart failure, or die suddenly within six months of diagnosis. Saddle thrombus reoccurs in about 50% of patients.

